

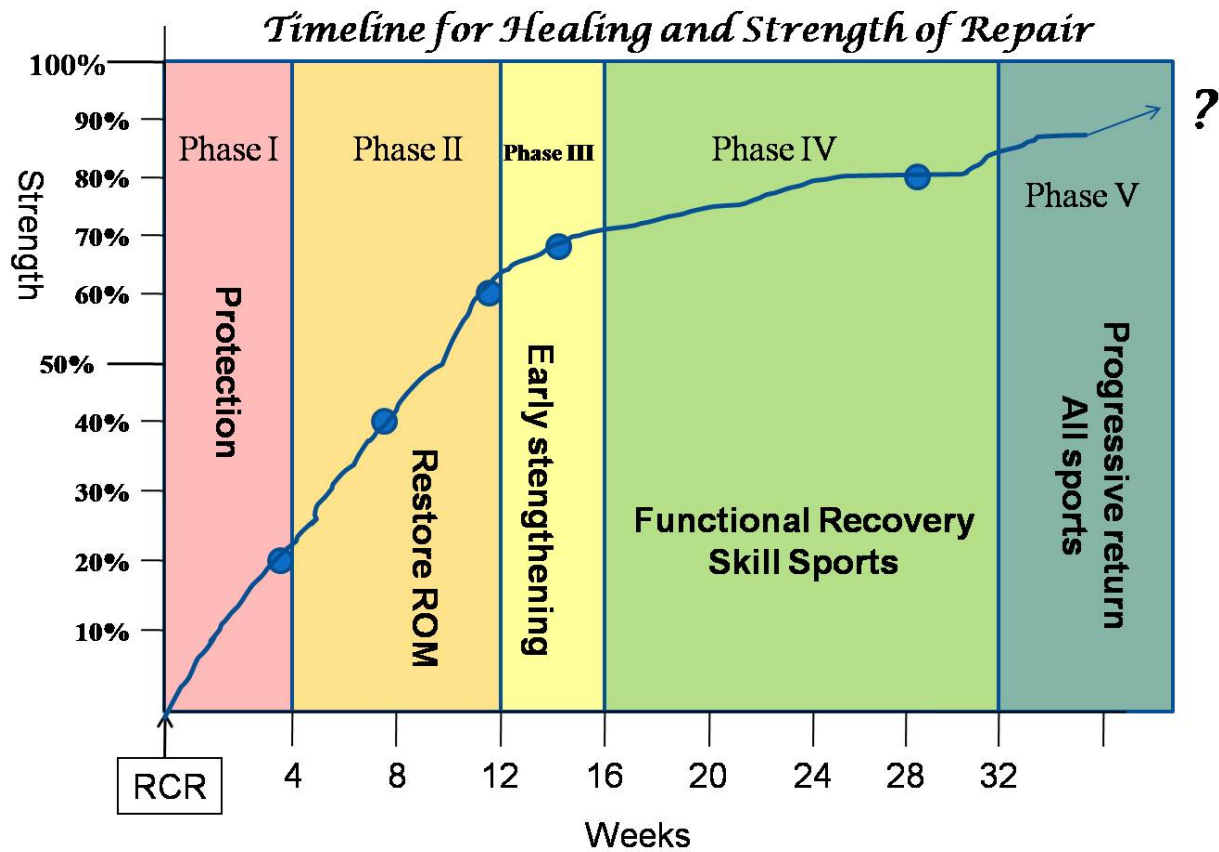
CURRENT CONCEPTS ON REHABILITATION PROGRAM AFTER ARTHROSCOPIC ROTATOR CUFF REPAIR: Scientific rationale

Jon J.P. Warner, MD
Lewis Shi, M.D.
Jeff Tompson, BA
The Harvard Shoulder Service
Boston, MA




What the current literature says....and does not say....an evidence-based approach to therapy after rotator cuff repair.

(To view our protocol go to http://www.bosshin.com/rotator_cuff_athologies/ and select “Arthroscopic Rotator Cuff Repair Protocol (Patient/Therapist Version)”



	PHASE I (4-6 WKS)	PHASE II (4-12 WKS)	PHASE III (12-16 WKS)	PHASE IV (16-32 WKS)	PHASE V (32- WKS)
CPM	NO	NO	NO	NO	NO
PASSIVE ROM	NO	YES	YES	YES	YES
ACTIVE ROM	NO	YES	YES	YES	YES
WATER THERAPY	NO	YES	YES	YES	YES
RESISTANCE (STRENGTHENING)	NO	NO	YES	YES	YES
SPORTS PARTICIPATION-SKILL	NO	NO	NO	YES	YES
SPORTS PARTICIPATION-CONTACT	NO	NO	NO	NO	YES
CYRYOTHERAPY	YES	YES	YES	YES	YES
STRENGTH OF TENDON REPAIR	20%	40%	60%	70%	80%



Clinical Articles and Reviews

Summary: Tissue quality and method of repair must be factored into individualized programs of care based in scientific evidence for the timeline of tendon healing and improvement in overall tendon-bone attachment strength.

J Am Acad Orthop Surg. 2006 Oct;14(11):599-609.

Rehabilitation of the rotator cuff: an evaluation-based approach.

Millett PJ, Wilcox RB 3rd, O'Holleran JD, Warner JJ.

Source

Harvard Medical School, Boston, MA, USA.

Abstract

Rotator cuff disease of the shoulder, a common condition, is often incapacitating. Whether nonsurgical or surgical, successful management of rotator cuff disease is dependent on appropriate rehabilitation. Numerous rehabilitation protocols for the management of rotator cuff disease are based primarily on anecdotal clinical observation. The available literature on shoulder rehabilitation, in conjunction with clinical observation that takes into consideration the underlying tissue quality and structural integrity of

the rotator cuff, can be compiled into a set of rehabilitation guidelines. The four phases of rehabilitation begin with maintaining and protecting the repair in the immediate postoperative period, followed by progression from early passive range of motion through return to preoperative levels of function.

Summary: Postoperative Stiffness is rare after arthroscopic rotator cuff repair despite an initial period of shoulder immobilization.

Arthroscopy. 2011 Jun;27(6):842-8.

Prevention and management of stiffness after arthroscopic rotator cuff repair: systematic review and implications for rotator cuff healing.

Denard PJ, Lädermann A, Burkhart SS.

Source

The San Antonio Orthopaedic Group, San Antonio, Texas, USA.

Abstract

PURPOSE:

To define the incidence of stiffness after arthroscopic rotator cuff repair (ARCR) and address the prevention and management of postoperative stiffness.

METHODS:

A PubMed search was performed using the combined terms "rotator cuff and stiffness," "shoulder and capsular release," and "capsular release and stiffness." Inclusion criteria were (1) primary outcome of postoperative shoulder stiffness, (2) Levels I to IV evidence, and (3) entirely arthroscopic technique for rotator cuff repair.

RESULTS:

Seven articles met our inclusion criteria. Two articles discussed the management of preoperative stiffness and ARCR. These articles managed preoperative stiffness differently, preventing an adequate comparison to provide recommendations. Three articles described both the incidence of and risk factors for postoperative stiffness after ARCR. The incidence of transient stiffness responsive to nonoperative management was 10%. The incidence of resistant stiffness that was permanent or required capsular release was 3.3%. Several risk factors for stiffness were identified in this review. Two articles focused on postoperative rehabilitation protocols and stiffness after ARCR. Overall, resistant postoperative stiffness was reported in 1.5% of patients with an immediate passive range-of-motion protocol, 4.5% of patients in a 6-week sling-immobilization protocol, and 0% of patients with a modified protocol. Three articles, all among the above mentioned articles, reported that arthroscopic capsular release for stiffness after ARCR improved motion to a level comparable to that in patients who did not require reoperation.

CONCLUSIONS:

The studies in this systematic review indicate that with ARCR, postoperative stiffness resistant to

nonoperative management is uncommon despite an initial immobilization period. In the setting of resistant postoperative stiffness, arthroscopic capsular release can successfully restore range of motion. ARCR allows a delayed mobilization protocol that may be important in achieving rotator cuff healing. The optimal management of preoperative stiffness in patients undergoing ARCR is inconclusive based on this review.

LEVEL OF EVIDENCE:

Level IV, systematic review of Level III and IV studies.

Summary: An accelerated protocol of immediate passive range of motion seems to be associated with less pain in the short term than immobilization of the shoulder after rotator cuff repair.

Acta Orthop Traumatol Turc. 2011;45(1):23-33. doi: 10.3944/AOTT.2011.2386.

Comparison of slow and accelerated rehabilitation protocol after arthroscopic rotator cuff repair: pain and functional activity.

Düzgün I, Baltacı G, Atay OA.

Source

Department of Physiotherapy and Rehabilitation, Faculty of Health Sciences, Gazi University, Ankara, Turkey. iremduzgun@gazi.edu.tr

Abstract

OBJECTIVES:

In this study, we sought to compare the effects of the slow and accelerated protocols on pain and functional activity level after arthroscopic rotator cuff repair.

METHODS:

The study included 29 patients (3 men, 26 women) who underwent arthroscopic repair of stage 2 and 3 rotator cuff tears. Patients were randomized in two groups: the accelerated protocol group (n=13) and slow protocol group (n=16). Patients in the accelerated protocol group participated in a preoperative rehabilitation program for 4-6 weeks. Patients were evaluated preoperatively and for 24 weeks postoperatively. Pain was assessed by visual analog scale, and functional activity level was assessed by The Disabilities of The Arm Shoulder and Hand (DASH) questionnaire. The active range of motion was initiated at week 3 after surgery for the accelerated rehabilitation protocol and at week 6 for the slow protocol. The rehabilitation program was completed by the 8th week with the accelerated protocol and by the 22nd week with the slow protocol.

RESULTS:

There was no significant difference between the slow and accelerated protocols with regard to pain at rest ($p>0.05$). However, the accelerated protocol was associated with less pain during activity at weeks 5 and

16, and with less pain at night during week 5 ($p<0.05$). The accelerated protocol was superior to the slow protocol in terms of functional activity level, as determined by DASH at weeks 8, 12, and 16 after surgery ($p<0.05$).

CONCLUSION:

The accelerated protocol is recommended to physical therapists during rehabilitation after arthroscopic rotator cuff repair to prevent the negative effects of immobilization and to support rapid reintegration to daily living activities.

PMID:

Summary: In at-risk patients (with calcific tendonitis, adhesive capsulitis, PASTA repair, concomitant labral repair, and single-tendon repair), a postoperative rehabilitation regimen that incorporates early closed-chain passive overhead motion can reduce the incidence of postoperative stiffness after arthroscopic rotator cuff repair

Arthroscopy. 2011 Feb;27(2):155-60. Epub 2010 Oct 20.

Reduction of postoperative stiffness after arthroscopic rotator cuff repair: results of a customized physical therapy regimen based on risk factors for stiffness.

Koo SS, Parsley BK, Burkhart SS, Schoolfield JD.

Abstract

PURPOSE:

The purpose of this study was to determine the benefits of a modified rehabilitation protocol (incorporating early closed-chain overhead stretching) in reducing the risk of postoperative stiffness after arthroscopic rotator cuff repair.

METHODS:

During a 17-month period, we performed primary arthroscopic rotator cuff repairs in 152 patients. After surgery, patients with risk factors identified in the previous study (calcific tendonitis, adhesive capsulitis, PASTA [partial articular surface tendon avulsion]-type rotator cuff repair, concomitant labral repair, or single-tendon cuff repair) were enrolled in a modified rehabilitation protocol that added early overhead closed-chain passive motion exercises to our standard protocol; alternatively, patients without risk factors received a standard conservative rehabilitation program. Historical controls were used and comprised patients in the senior author's practice who all received the conservative rehabilitation protocol. The prevalence of postoperative stiffness was compared between the historical cohort and current study patients by use of Fisher exact tests.

RESULTS:

Among the 152 patients studied, 79 were positive for at least 1 of the specified risk factors and received

the modified protocol. Postoperative stiffness developed in none of the 79 patients enrolled in the modified program. This finding represented a significant improvement (Fisher exact test, $P = .004$) over the historical controls, in which 18 of the 231 at-risk patients had significant postoperative stiffness develop.

CONCLUSIONS:

In at-risk patients (with calcific tendonitis, adhesive capsulitis, PASTA repair, concomitant labral repair, and single-tendon repair), a postoperative rehabilitation regimen that incorporates early closed-chain passive overhead motion can reduce the incidence of postoperative stiffness after arthroscopic rotator cuff repair.

Summary: Early restriction of motion after repair of large rotator cuff tendon tears does not lead to stiffness when patients are evaluated one year after surgery; and early immobilization is associated with a trend toward a higher healing rate than patients with institution of early motion after surgery.

J Shoulder Elbow Surg. 2010 Oct;19(7):1034-9. Epub 2010 Jul 24.

Does slower rehabilitation after arthroscopic rotator cuff repair lead to long-term stiffness?

Parsons BO, Gruson KI, Chen DD, Harrison AK, Gladstone J, Flatow EL.

Source

Leni & Peter May Department of Orthopaedic Surgery, Mount Sinai School of Medicine, New York, NY 10029, USA. bradford.parsons@mountsinai.org

Abstract

HYPOTHESIS:

Conservative rehabilitation after arthroscopic rotator cuff repair does not result in long-term stiffness and improves rates of tendon healing.

MATERIALS AND METHODS:

We retrospectively evaluated 43 patients with full-thickness rotator cuff tears who underwent a standardized, conservative protocol of full-time sling immobilization without formal therapy for 6 weeks after arthroscopic repair. At 6 to 8 weeks of follow-up, we categorized patients as "stiff" if they demonstrated forward elevation of less than 100° and external rotation of less than 30° passively; all others were designated "nonstiff." Active range of motion in forward elevation, external rotation, and internal rotation was assessed at 3 months, 6 months, and 1 year. American Shoulder and Elbow Surgeons (ASES) and Constant-Murley scores were assessed at 1 year. Follow-up magnetic resonance imaging (MRI) was obtained in all patients to assess tendon healing.

RESULTS:

Ten patients (23%) were considered stiff after rotator cuff surgery. At 1 year, there was no difference in

mean forward elevation (166° vs 161°, $P = .2$), external rotation (62° vs. 58.4°, $P = .5$), or internal rotation (T7.4 vs T8.2, $P = .07$) between the stiff and nonstiff groups, respectively. There were no differences in final ASES (83 vs 79, $P = .57$) and Constant-Murley scores (77 vs. 74, $P = .5$). Repeat MRI suggested a trend toward a lower retear rate among the stiff patients (70% intact in stiff group vs 36% in nonstiff group, $P = .079$). Two clinically significant cuff retears occurred in the nonstiff cohort.

DISCUSSION:

Concerns for recalcitrant stiffness have led some to favor early postoperative therapy. We found that early restriction of motion did not lead to long-term stiffness after arthroscopic rotator cuff repair, even in patients who were clinically stiff in the early postoperative period.

CONCLUSIONS:

Sling immobilization for 6 weeks after arthroscopic rotator cuff repair does not result in increased long-term stiffness and may improve the rate of tendon healing.

Summary: While Continuous Passive Motion machines offer some advantage of faster return of motion after rotator cuff repair, there is no difference when compared with individuals performing passive self-assisted exercises after rotator cuff repair surgery.

Musculoskelet Surg. 2010 May;94 Suppl 1:S79-83.

Effects of one-month continuous passive motion after arthroscopic rotator cuff repair: results at 1-year follow-up of a prospective randomized study.

Garofalo R, Conti M, Notarnicola A, Maradei L, Giardella A, Castagna A.

Source

Orthopaedic and Traumatologic Unit, Regional Hospital F. Miulli, Bari, Italy.
raffaelegarofalo@gmail.com

Abstract

The study included 100 patients who underwent an arthroscopic rotator cuff repair. All patients suffered about a rotator cuff tear that was repaired arthroscopically with a suture anchor technique. Immediately postoperatively, patients were randomly allocated to one of two different postoperative physiotherapy regimens: passive self-assisted range of motion exercise (controls: 46 patients) versus passive self-assisted range of motion exercise associated with use of continuous passive motion (CPM) for a total of 2 h per day (experimental group: 54 patients), for 4 weeks. After this time, all the patients of both groups underwent the same physical therapy protocol. An independent examiner assessed the patients at 2.5, 6 and 12 months particularly about pain with the VAS scale (0-10) and the range of motion (ROM). Our findings show that postoperative treatment of an arthroscopic rotator cuff repair with passive self-assisted exercises associated with 2-h CPM a day provides a significant advantage in terms of ROM improvement and pain relief when compared to passive self-assisted exercise alone, at the short-term follow-up. No

significant differences between the two groups were observed at 1 year postoperatively.

Summary: An individualized rehabilitation program beginning closed-chain overhead stretches reduces stiffness after rotator cuff repair in patients at risk for stiffness.

Clin Sports Med. 2010 Apr;29(2):203-11, vii.

Rehabilitation following arthroscopic rotator cuff repair.

Koo SS, Burkhart SS.

Source

The San Antonio Orthopaedic Group, 150 East Sonterra Boulevard, Suite 300, San Antonio, TX 78258, USA.

Abstract

The postoperative rehabilitation program is critical for the successful arthroscopic treatment of rotator cuff injury. The authors' experience has confirmed that the best clinical results (restoration of strength, motion, and relief of pain) following rotator cuff repair are achieved after a durable repair of tendon to bone that heals in its entirety. Therefore, the senior author (SSB) has adopted a customized rehabilitation protocol to optimize postoperative range of motion while maintaining rotator cuff integrity. A customized rehabilitation program that begins closed-chained overhead stretches (table slides) early for groups at risk for developing stiffness and delays overhead stretches for the remaining patients until 6 weeks is best to avoid stiffness without potentially increasing the risk of rerupture in the early postoperative period.

Summary: Incorrectly performed pendulum exercises activate the supraspinatus and place at risk the rotator cuff repair if performed in the initial period after arthroscopic repair.

J Orthop Sports Phys Ther. 2010 Apr;40(4):230-7.

Activation of the shoulder musculature during pendulum exercises and light activities.

Long JL, Ruberte Thiele RA, Skendzel JG, Jeon J, Hughes RE, Miller BS, Carpenter JE.

Source

Department of Orthopaedic Surgery, University of Michigan, Ann Arbor, MI, USA.

Abstract

STUDY DESIGN:

Prospective, single-group, repeated-measures design.

OBJECTIVES:

To evaluate electromyographic (EMG) signal amplitude in the supraspinatus, infraspinatus, and deltoid muscles during pendulum exercises and light activities in a group of healthy subjects.

BACKGROUND:

There are numerous rehabilitation protocols used after rotator cuff repair. One of the most commonly used exercises in these protocols is the pendulum. Patients can easily perform these exercises incorrectly, and may also perform light activities of daily living without knowing that they may be putting excessive stress on the repair. The effect of improperly performed pendulum exercises and light activities after rotator cuff repair is unknown.

METHODS:

Muscle activity was recorded in 13 subjects performing pendulum exercises incorrectly and correctly in both large (51-cm) and small (20-cm) diameters, and while typing, drinking, and brushing their teeth.

RESULTS:

Incorrect and correct large pendulums and drinking elicited more than 15% maximum voluntary isometric contraction in the supraspinatus and infraspinatus. The supraspinatus EMG signal amplitude was greater during large, incorrectly performed pendulums than during those performed correctly. Both correct and incorrect large pendulums resulted in statistically higher muscle activity in the supraspinatus than the small pendulums.

CONCLUSION:

Larger pendulums may require more force than is desirable early in rehabilitation after rotator cuff repair

Summary: Factors affecting tendon healing are patient age, size and extent of tendon tear, and fatty muscle degeneration of the rotator cuff muscle.

Clin Orthop Surg. 2009 Jun;1(2):96-104. Epub 2009 May 30.

The factors affecting the clinical outcome and integrity of arthroscopically repaired rotator cuff tears of the shoulder.

Cho NS, Rhee YG.

Department of Orthopaedic Surgery, Kyung Hee University School of Medicine, Seoul, Korea.

Abstract

BACKGROUND:

The purpose of this study was to evaluate the functional and anatomic results of arthroscopic rotator cuff

repair, and to analyze the factors affecting the integrity of arthroscopically repaired rotator cuff tears of the shoulder.

METHODS:

One hundred sixty-nine consecutive shoulders that underwent arthroscopic rotator cuff repair, had a postoperative MRI evaluation and were followed for at least two years were enrolled in this study. The mean age was 57.6 years (range, 38 to 74 years) and the mean follow-up period was 39 months (range, 24 to 83 months).

RESULTS:

The rotator cuff was completely healed in 131 (77.5%) out of 169 shoulders and recurrent tears occurred in 38 shoulders (22.5%). At the last follow-up visit, the mean score for pain during motion was 1.53 (range, 0 to 4) in the completely healed group and 1.59 (range, 0 to 4) in the group with recurrent tears ($p = 0.092$). The average elevation strength was 7.87 kg (range, 4.96 to 11.62 kg) and 5.25 kg (range, 4.15 to 8.13 kg) and the mean University of California at Los Angeles score was 30.96 (range, 26 to 35) and 30.64 (range, 23 to 34), respectively ($p < 0.001$, $p = 0.798$). The complete healing rate was 87.8% in the group less than 50 years of age (49 shoulders), 79.4% in the group over 51 years but less than 60 years of age (68 shoulders), and 65.4% in the group over 61 years of age (52 shoulders, $p = 0.049$); it was 96.7% in the group with small-sized tears (30 shoulders), 87.3% in the group with medium-sized tears (71 shoulders), and 58.8% in the group with large-sized or massive tears (68 shoulders, $p = 0.009$). All of the rotator cuffs with a global fatty degeneration index of greater than two preoperatively had recurrent tears.

CONCLUSIONS:

Arthroscopic repair of full-thickness rotator cuff tears led to a relatively high rate of recurrent defects. However, the minimum two-year follow up demonstrated excellent pain relief and improvement in the ability to perform the activities of daily living, despite the structural failures. The factors affecting tendon healing were the patient's age, the size and extent of the tear, and the presence of fatty degeneration in the rotator cuff muscle.

Summary: A 4.9% incidence of stiffness was observed after arthroscopic rotator cuff repair with risk factors being calcific tendinitis, adhesive capsulitis, single-tendon cuff repair, PASTA repair, being under 50 years of age, and having Workers' Compensation insurance

Arthroscopy. 2009 Aug;25(8):880-90.

Incidence and treatment of postoperative stiffness following arthroscopic rotator cuff repair.

Huberty DP, Schoolfield JD, Brady PC, Vadala AP, Arrigoni P, Burkhart SS.

Oregon Orthopedics and Sports Medicine Clinic, LLP, Oregon City, Oregon, USA.

Abstract

PURPOSE:

The purpose of this study was to determine the incidence of clinically significant postoperative stiffness following arthroscopic rotator cuff repair. This study also sought to determine the clinical and surgical factors that were associated with higher rates of postoperative stiffness. Finally, we analyzed the result of arthroscopic lysis of adhesions and capsular release for treatment of patients who developed refractory postoperative stiffness 4 to 19 months (median, 8 months) following arthroscopic rotator cuff repair.

METHODS:

A retrospective review of a consecutive series of arthroscopic rotator cuff repairs was conducted. During a 3-year time period, the senior author (S.S.B.) performed 489 arthroscopic rotator cuff repairs. The operative indications, technique of the rotator cuff repair, and the rehabilitation protocol were essentially unchanged during this time period. Demographic data, comorbid medical conditions, rotator cuff tear description, technique of repair, and concomitant surgical procedures were evaluated for their effect on stiffness. All office evaluations were reviewed to determine the pre- and postoperative motion, pain scores, functional strength, and patient satisfaction. Patients who were dissatisfied because of the development of postoperative stiffness underwent secondary arthroscopic lysis of adhesions. The final result of the secondary lysis of adhesions and capsular release were analyzed.

RESULTS:

In total, 24 patients (4.9%) were dissatisfied with the result of their procedure because of the development of postoperative stiffness, which was more likely ($P < .05$) to develop in patients with Workers' Compensation insurance (8.6%), patients younger than 50 years of age (8.6%), those with a coexisting diagnosis of calcific tendonitis (16.7%) or adhesive capsulitis (15.0%) requiring additional postoperative therapy, partial articular-sided tendon avulsion (PASTA) type rotator cuff tear (13.5%), or concomitant labral repair (11.0%). Patients with concomitant coracoplasty (2.3%) or tears larger in size and/or involving more tendons were less likely ($P < .05$) to develop postoperative stiffness. Among 90 patients positive for selected risk factors (adhesive capsulitis, excision of calcific deposits, single-tendon repair, PASTA repair, or any labral repair without a concomitant coracoplasty), 12 (13.3%) developed postoperative stiffness ($P < .001$). This overall clinical risk factor combined with Workers' Compensation insurance identified 16 of the 24 cases resulting in a sensitivity of 66.7% and a specificity of 64.5%. All 24 patients who experienced postoperative stiffness elected to undergo arthroscopic lysis of adhesions and capsular release, which was performed from 4 to 19 months (median, 8 months) after the rotator cuff repair. During second-look arthroscopy, 23 patients (95.8%) were noted to have complete healing of the original pathology. Following capsular release, all 24 patients were satisfied with the overall result of their treatment.

CONCLUSIONS:

In a series of 489 consecutive arthroscopic rotator cuff repairs, we found that 24 patients (4.9%) developed postoperative stiffness. Risk factors for postoperative stiffness were calcific tendinitis, adhesive capsulitis, single-tendon cuff repair, PASTA repair, being under 50 years of age, and having Workers' Compensation insurance. Twenty-three of 24 patients (95.8%) showed complete healing of the rotator cuff. Arthroscopic release resulted in normal motion in all cases.

LEVEL OF EVIDENCE:

Level IV, therapeutic case series.

Summary; Water therapy is a feasible adjunct to standard physical therapy but there is no scientific evidence for an advantage over routine dry land therapy.

Physiother Res Int. 2008 Sep;13(3):153-61.

The addition of aquatic therapy to rehabilitation following surgical rotator cuff repair: a feasibility study.

Brady B, Redfern J, MacDougal G, Williams J.

Discipline of Physiotherapy, School of Health Sciences, University of Sydney, NSW, Australia.
bernadette.brady@sswahs.nsw.gov.au

Abstract

BACKGROUND AND PURPOSE:

Rotator cuff tears are frequently encountered in medical outpatient settings and often require surgical repair to achieve desirable functional outcomes. However, the optimal form of post-operative rehabilitation of rotator cuff repairs remains unidentified by the research literature. The aim of this study was to determine the feasibility of implementing and investigating the effect of a combined aquatic and land-based rehabilitation programme in the post-operative rehabilitation of rotator cuff tears.

METHODS:

A cohort of 18 subjects undergoing rotator cuff repair were examined over a treatment period of 12 weeks. Twelve subjects participated in a combined aquatic and land-based programme, while six subjects received a standard land-based protocol. Passive range of motion and the Western Ontario Rotator Cuff Index outcomes were measured pre-operatively and at three, six and 12 weeks, post-operatively. Subjective responses on patient's assurance and confidence in the value of the exercises (questionnaire using an 11-point Visual Analogue Scale (VAS)) were collected at 12 weeks for both groups.

RESULTS:

There was a significant improvement in both range of motion and Western Ontario Rotator Cuff scores in all subjects with treatment ($p < 0.001$). Furthermore, participation in aquatic therapy significantly improved passive flexion range of motion measures at three weeks (mean 46 degrees, 95% CI 17-75, $p = 0.005$) and six weeks (30 degrees, 95% CI 8-51, $p = 0.01$). There was no significant difference in the attendance rates (80% in both groups) or patients perceptions of the programmes (100% confidence and assurance in both groups).

CONCLUSION:

The implementation of a combined aquatic and land-based physiotherapy programme following surgical repair of the rotator cuff is feasible and presents a potential viable alternative to conventional land-based exercise with comparable outcomes.

Summary; There seems to be no difference between two types of therapy programs, standardized and individualized.

Aust J Physiother. 2004;50(2):77-83.

A randomised clinical trial evaluating the efficacy of physiotherapy after rotator cuff repair.

Hayes K, Ginn KA, Walton JR, Szomor ZL, Murrell GA.

Source

St George Hospital, University of New South Wales, Australia.

Abstract

The optimal form of rehabilitation after rotator cuff repair has yet to be determined. A randomised clinical trial was undertaken to compare outcomes for two forms of rehabilitation for this condition: individualised supervised physiotherapy treatment, and a standardised unsupervised home exercise regime. Fifty-eight volunteers with all sizes of operatively repaired rotator cuff tears were allocated randomly to one of the two treatment groups. All subjects received a standardised home exercise regime. Subjects who were randomised to the physiotherapy group received additional individualised treatment. Independent, blinded assessments of range of motion, muscle force and functional outcome measures were performed pre-operatively, and at six, 12 and 24 weeks postoperation. At six, 12 and 24 weeks post-operation, comparable outcomes were demonstrated for both rehabilitation groups. By 24 weeks post-operation, most subjects demonstrated outcomes that were consistent with a favourable recovery, regardless of rehabilitation mode. On the basis of these results, outcomes for subjects allocated to individualised physiotherapy treatment after rotator cuff repair are no better than for subjects allocated to a standardised home exercise regime.

Summary; Cryotherapy immediately following surgery reduces pain and permits a more effective therapy program.

J Shoulder Elbow Surg. 1996 Jan-Feb;5(1):62-8.

The efficacy of cryotherapy in the postoperative shoulder.

Speer KP, Warren RF, Horowitz L.

Source

Sports Medicine Department, Hospital for Special Surgery, New York, USA.

Abstract

We report the results of an outcome study that used visual analog scales to evaluate the efficacy of cryotherapy in the postoperative shoulder. This prospective study included 50 consecutive patients admitted to the hospital for at least one night after anterior shoulder stabilization, rotator cuff repair, or total shoulder replacement. The patients were randomized: 25 were fitted with a cryotherapy device in the operating room, and 25 were not. Otherwise, postoperative treatment was identical for the two groups, including types of analgesic agents given. Visual analog responses were converted to numeric

values by simple measurement techniques. The scales assessed pain, comfort, sleep, analgesic use, and overall satisfaction. On the night of the operation the pain was less severe and occurred less often in the cryotherapy group. Those in the cryotherapy group slept better on the night of the operation and perceived the need to use pain medicine less often in comparison with those in the noncryotherapy group. By postoperative day 10 patients in the cryotherapy group reported their shoulders hurt less often and with less severity. Swelling was less, and shoulder movement hurt less during rehabilitation, enhancing the rehabilitative effort. Cryotherapy offers a number of benefits for care of patients in the immediate postoperative period.

Summary: Cryotherapy immediately following surgery reduces pain and allows for a more normal return to sleep, thus it improves patients satisfaction in the immediate postoperative period.

J Shoulder Elbow Surg. 2001 Nov-Dec;10(6):522-5.

The efficacy of continuous cryotherapy on the postoperative shoulder: a prospective, randomized investigation.

Singh H, Osbahr DC, Holovac TF, Cawley PW, Speer KP.

Source

Division of Orthopaedic Surgery, Duke University Medical Center, Durham, NC, USA.

Abstract

This prospective, randomized investigation evaluated the efficacy of cryotherapy on subjective responses after both open and arthroscopic procedures on the shoulder. Seventy patients were randomly assigned to one of two study groups: (1) continuous cryotherapy group and (2) age-matched control group. Visual analog scales were used to assess subjective responses on postoperative days 1, 7, 14, and 21. On day 1, patients receiving cryotherapy reported significantly less pain during sleep and significantly more comfort in bed and rated their sleep as more restful than the control subjects. During days 7 through 21, cryotherapy subjects reported a significant reduction in frequency and intensity of pain, as well as less pain during shoulder rehabilitation, than the control subjects. These results indicate that cryotherapy is an effective method for postoperative pain control because it decreases the severity and frequency of pain and allows a return to normal sleep patterns while increasing overall postoperative comfort and satisfaction.

Summary: Cryotherapy causes significant reduction of both glenohumeral joint and subacromial space temperatures during the first 23 postoperative hours. This decrease in temperature may decrease proteolytic enzyme activity that can be detrimental to articular cartilage. It also shows that cryotherapy is an effective nonpharmacological method of pain control.

Arthroscopy. 2002 Sep;18(7):748-54.

The effect of continuous cryotherapy on glenohumeral joint and subacromial space temperatures in the postoperative shoulder.

Osbahr DC, Cawley PW, Speer KP.

Source

University of North Carolina School of Medicine, Chapel Hill, USA.

Abstract

PURPOSE:

The objective of this investigation was to determine the effect of continuous cryotherapy on glenohumeral joint and subacromial space temperatures in the postoperative shoulder.

TYPE OF STUDY:

Prospective, randomized, and controlled clinical trial.

METHODS:

Twenty patients (10 cryotherapy, 10 controls) with a full-thickness rotator cuff repair were monitored with temperature sensors in the glenohumeral joint and subacromial space of the shoulder for 23 postoperative hours. Statistical analysis ($P < .05$) was performed using the Mann-Whitney rank-sum test.

RESULTS:

In comparing the cryotherapy and control groups, analysis of the glenohumeral joint and subacromial space temperatures revealed a statistical significance at 4, 8, and 23, and 4, 8, 16, and 20 postoperative hours, respectively. In addition, a trend toward a temperature-rising phase occurs from 4 to 12 hours and is followed by a trend toward a thermostatic phase from 12 to 23 hours during which temperatures remain relatively constant. The subacromial space was consistently cooler than the glenohumeral joint by an interval between 0.07 degrees C to 0.50 degrees C except at 23 hours postoperative where the glenohumeral joint was 0.05 degrees C cooler.

CONCLUSIONS:

Continuous cryotherapy causes a statistically significant reduction of both glenohumeral joint and subacromial space temperatures in the shoulder at variable times during the first 23 postoperative hours. Previous investigations have shown that minor elevations in intra-articular temperature can stimulate proteolytic enzyme activity, which has detrimental effects on articular cartilage. Previous research has also shown that cryotherapy is an effective nonpharmacological method of pain control. Yet the literature has assumed that the effects of cryotherapy are part of the basic analgesia mechanism because of a

reduction in joint temperature. Our results affirm that reductions in glenohumeral joint and subacromial space temperatures in the postoperative shoulder do occur, leading to potential benefits of continuous cryotherapy as an effective mode of pain control in the postoperative care of patients.

Summary: Cryotherapy does not reduced subacromial and glenohumeral joint temperature in this 10 patient randomized control study.

Arthroscopy. 1997 Aug;13(4):461-4.

Penetration of cryotherapy in treatment after shoulder arthroscopy.

Levy AS, Kelly B, Lintner S, Speer K.

Source

Department of Orthopaedic Surgery, New Jersey Medical School, Newark, USA.

Abstract

Fifteen patients undergoing shoulder arthroscopy had indwelling temperature probes placed in the glenohumeral and subacromial spaces. All shoulders underwent diagnostic arthroscopy and debridement of the subacromial space. Cryotherapy was delivered to the shoulder via a Cryo/Cuff (AirCast, Summit, NJ) and temperatures were monitored for 90 minutes. Ten shoulders received cryotherapy and 5 were used as controls. Before cryotherapy, temperature averaged 34 degrees C in the glenohumeral joint and 31 degrees C in the subacromial space. No significant difference was seen between the temperatures recorded in the cold therapy and control groups for either the glenohumeral or subacromial space. In all cases, the subacromial space averaged 1 degree cooler than the glenohumeral joint at the conclusions of arthroscopy. These slowly equalized to an average of 35 degrees postoperatively. The present study shows that surface-applied cryotherapy does not penetrate either the glenohumeral joint or the subacromial space. Attention must be turned elsewhere to delineate how cryotherapy works.

Summary: Cigarette smoking increases the risk for rotator cuff tears and patients should be told to cease smoking both prior to and after rotator cuff repair surgery.

Clin Orthop Relat Res. 2010 Jun;468(6):1534-41. Epub 2009 Mar 13.

Cigarette smoking increases the risk for rotator cuff tears.

Baumgarten KM, Gerlach D, Galatz LM, Teefey SA, Middleton WD, Ditsios K, Yamaguchi K.

Source

Orthopedic Institute, 810 E 23rd Street, Sioux Falls, SD 57117, USA. Kbaumga@yahoo.com

Abstract

There is little available evidence regarding risk factors for rotator cuff tears. Cigarette smoking may be an important risk factor for rotator cuff disease. The purpose of this study was to determine if cigarette smoking correlates with an increased risk for rotator cuff tears in patients who present with shoulder pain. A questionnaire was administered to 586 consecutive patients 18 years of age or older who had a diagnostic shoulder ultrasound for unilateral, atraumatic shoulder pain with no history of shoulder surgery. Three hundred seventy-five patients had a rotator cuff tear and 211 patients did not. Data regarding cigarette smoking were obtained for 584 of 586 patients. A history of smoking (61.9% versus 48.3%), smoking within the last 10 years (35.2% versus 30.1%), mean duration of smoking (23.4 versus 20.2 years), mean packs per day of smoking (1.25 versus 1.10 packs per day), and mean pack-years of smoking (30.1 versus 22.0) correlated with an increased risk for rotator cuff tear. We observed a dose-dependent and time-dependent relationship between smoking and rotator cuff tears. We observed a strong association between smoking and rotator cuff disease. This may indicate smoking is an important risk factor for the development of rotator cuff tears. Level of Evidence: Level III, prognostic study. See Guidelines for Authors for a complete description of levels of evidence.

Summary: Delayed therapy after rotator cuff repair does not affect ultimate range of motion and may be associated with a higher healing rate.

Presentation at Annual Open Meeting of American Shoulder and Elbow Surgeons, San Diego, 2011- Neer award paper

Prospective randomized study of arthroscopic rotator cuff repair using an early versus delayed postoperative physical therapy protocol.

Derek Cuff, MD, Derek Pupello, MBA.

Conclusion: Patient who underwent arthroscopic rotator cuff repair and then prescribed a postoperative protocol with early or delayed initiation of passive range of motion demonstrated very similar outcomes and range of motion at one year. There was a slightly higher rotator cuff healing rate in the delayed passive range of motion group compared to the early passive range of motion group (91% vs. 85%).

BASIC SCIENCE ARTICLES

Summary: Structural characteristics of a repaired rotator cuff tendon after a chronic tear place it at risk with early motion following surgery.

Plasticity of muscle architecture after supraspinatus tears.

Ward SR, Sarver JJ, Eng CM, Kwan A, Würgler-Hauri CC, Perry SM, Williams GR, Soslowky LJ, Lieber RL.

Source

Department of Radiology, University of California and Veterans Administration Medical Centers, San Diego, CA, USA. srward@ucsd.edu

Abstract

STUDY DESIGN:

Controlled laboratory study.

OBJECTIVES:

To measure the architectural properties of rat supraspinatus muscle after a complete detachment of its distal tendon.

METHODS:

Supraspinatus muscles were released from the left humerus of 29 Sprague-Dawley rats (mass, 400-450 g), and the animals were returned to cage activity for 2 weeks (n=12), 4 weeks (n=9), or 9 weeks (n=8), before euthanasia. Measurements of muscle mass, pennation angle, fiber bundle length (sarcomere number), and sarcomere length permitted calculation of normalized fiber length, serial sarcomere number, and physiological cross-sectional area.

RESULTS:

Coronal oblique sections of the supraspinatus confirmed surgical transection of the supraspinatus muscle at 2 weeks, with reattachment by 4 weeks. Muscle mass and length were significantly lower in released muscles at 2 weeks, 4 weeks, and 9 weeks. Sarcomere lengths in released muscles were significantly shorter at 2 weeks but not different by 4 weeks. Sarcomere number was significantly reduced at 2 and 4 weeks, but returned to control values by 9 weeks. The opposing effects of smaller mass and shorter fibers produced significantly smaller physiological cross-sectional area at 2 weeks, but physiological cross-sectional area returned to control levels by 4 weeks.

CONCLUSIONS:

Release of the supraspinatus muscle produced early radial and longitudinal atrophy of the muscle. The functional implications of these adaptations would be most profound at early time points (particularly relevant for rehabilitation), when the muscle remains smaller in cross-sectional area and, due to reduced sarcomere number, would be forced to operate over a wider range of the length-tension curve and at higher velocities, all adaptations resulting in compromised force-generating capacity. These data are relevant to physical therapy because they provide tissue-level insights into impaired muscle and shoulder function following rotator cuff injury.

Summary: Histological maturation of the bone-tendon healing remains immature (weaker) during the first 15 weeks after surgery, so the rehabilitation program after surgical rotator cuff repair must not load the tendon-bone interface with resistance exercises until 12-15 weeks after surgery.

J Bone Joint Surg Br. 2010 Apr;92(4):586-94.

Histological evaluation of repair of the rotator cuff in a primate model.

Sonnabend DH, Howlett CR, Young AA.

Source

Department of Orthopaedic and Traumatic Surgery, Royal North Shore Hospital, Sydney, New South Wales 2065, Australia. davidso@med.usyd.edu.au

Abstract

The establishment of a suitable animal model of repair of the rotator cuff is difficult since the presence of a true rotator cuff anatomically appears to be restricted almost exclusively to advanced primates. Our observational study describes the healing process after repair of the cuff in a primate model. Lesions were prepared and repaired in eight 'middle-aged' baboons. Two each were killed at four, eight, 12 and 15 weeks post-operatively. The bone-tendon repair zones were assessed macroscopically and histologically. Healing of the baboon supraspinatus involved a sequence of stages resulting in the reestablishment of the bone-tendon junction. It was not uniform and occurred more rapidly at the sites of suture fixation than between them. Four weeks after repair the bone-tendon healing was immature. Whereas macroscopically the repair appeared to be healed at eight weeks, the Sharpey fibres holding the repair together did not appear in any considerable number before 12 weeks. By 15 weeks, the bone-tendon junction was almost, but not quite mature. Our results support the use of a post-operative rehabilitation programme in man which protects the surgical repair for at least 12 to 15 weeks in order to allow maturation of tendon-to-bone healing.

Summary: After initial immobilization of a shoulder following rotator cuff repair, too vigorous activity is detrimental to mechanical properties of the rotator cuff (risk to the repair.)

J Orthop Res. 2010 Jul;28(7):841-5.

Exercise following a short immobilization period is detrimental to tendon properties and joint mechanics in a rat rotator cuff injury model.

Peltz CD, Sarver JJ, Dourte LM, Würgler-Hauri CC, Williams GR, Soslowsky LJ.

Source

McKay Orthopaedic Research Laboratory, University of Pennsylvania, 424 Stemmler Hall, 36th and Hamilton Walk, Philadelphia, Pennsylvania 19104, USA.

Abstract

Rotator cuff tears are a common clinical problem that can result in pain and disability. Previous studies in a rat model showed enhanced tendon to bone healing with postoperative immobilization. The objective of this study was to determine the effect of postimmobilization activity level on insertion site properties and joint mechanics in a rat model. Our hypothesis was that exercise following a short period of immobilization will cause detrimental changes in insertion site properties compared to cage activity following the same period of immobilization, but that passive shoulder mechanics will not be affected. We detached and repaired the supraspinatus tendon of 22 Sprague-Dawley rats, and the injured shoulder was immobilized postoperatively for 2 weeks. Following immobilization, rats were prescribed cage activity or exercise for 12 weeks. Passive shoulder mechanics were determined, and following euthanasia, tendon cross-sectional area and mechanical properties were measured. Exercise following immobilization resulted in significant decreases compared to cage activity in range of motion, tendon stiffness, modulus, percent relaxation, and several parameters from both a structurally based elastic model and a quasi-linear viscoelastic model. Therefore, we conclude that after a short period of immobilization, increased activity is detrimental to both tendon mechanical properties and shoulder joint mechanics, presumably due to increased scar production.

Summary: Passive range of motion does not affect collagen organization or mechanical properties of a repaired rotator cuff tendon when performed immediately after surgery.

J Bone Joint Surg Am. 2009 Oct;91(10):2421-9.

The effect of postoperative passive motion on rotator cuff healing in a rat model.

Peltz CD, Dourte LM, Kuntz AF, Sarver JJ, Kim SY, Williams GR, Soslowsky LJ.

McKay Orthopaedic Research Laboratory, University of Pennsylvania, 424 Stemmler Hall, 36th and Hamilton Walk, Philadelphia, PA 19104, USA. soslowsk@upenn.edu

Abstract

BACKGROUND:

Surgical repairs of torn rotator cuff tendons frequently fail. Immobilization has been shown to improve tissue mechanical properties in an animal model of rotator cuff repair, and passive motion has been shown to improve joint mechanics in animal models of flexor tendon repair. Our objective was to determine if daily passive motion would improve joint mechanics in comparison with continuous immobilization in a rat rotator cuff repair model. We hypothesized that daily passive motion would result in improved passive shoulder joint mechanics in comparison with continuous immobilization initially and that there would be no differences in passive joint mechanics or insertion site mechanical properties after four weeks of remobilization.

METHODS:

A supraspinatus injury was created and was surgically repaired in sixty-five Sprague-Dawley rats. Rats were separated into three postoperative groups (continuous immobilization, passive motion protocol 1,

and passive motion protocol 2) for two weeks before all underwent a remobilization protocol for four weeks. Serial measurements of passive shoulder mechanics (internal and external range of motion and joint stiffness) were made before surgery and at two and six weeks after surgery. After the animals were killed, collagen organization and mechanical properties of the tendon-to-bone insertion site were determined.

RESULTS:

Total range of motion for both passive motion groups (49% and 45% of the pre-injury values) was less than that for the continuous immobilization group (59% of the pre-injury value) at two weeks and remained significantly less following four weeks of remobilization exercise. Joint stiffness at two weeks was increased for both passive motion groups in comparison with the continuous immobilization group. At both two and six weeks after repair, internal range of motion was significantly decreased whereas external range of motion was not. There were no differences between the groups in terms of collagen organization or mechanical properties.

CONCLUSIONS:

In this model, immediate postoperative passive motion was found to be detrimental to passive shoulder mechanics. We speculate that passive motion results in increased scar formation in the subacromial space, thereby resulting in decreased range of motion and increased joint stiffness. Passive motion had no effect on collagen organization or tendon mechanical properties measured six weeks after surgery.

Summary: Corticosteroid injection should not be given immediately before rotator cuff repair surgery or immediately after as it weakens the tendon tissue.

J Bone Joint Surg Am. 2009 May;91(5):1172-80.

Effect of corticosteroids on the biomechanical strength of rat rotator cuff tendon.

Mikolyzk DK, Wei AS, Tonino P, Marra G, Williams DA, Himes RD, Wezeman FH, Callaci JJ.

Source

Department of Orthopaedic Surgery and Rehabilitation, Loyola University Medical Center, Maywood, IL 60153, USA. dmikoly@lumc.edu

Abstract

BACKGROUND:

The effect of corticosteroids on tendon properties is poorly understood, and current data are contradictory and diverse. The biomechanical effect of steroids on rotator cuff tendon has not been studied, to our knowledge. The current study was undertaken to characterize the biomechanical effects of corticosteroid exposure on both uninjured and injured rat rotator cuff tendon.

METHODS:

One hundred and twenty-three male Sprague-Dawley rats were randomly assigned to four groups: control (C), tendon injury (I), steroid exposure (S), and tendon injury plus steroid exposure (I+S). Unilateral

tendon injuries consisting of a full-thickness defect across 50% of the total width of the infraspinatus tendon were created. Steroid treatment consisted of a single dose of methylprednisolone placed into the subacromial space. At one, three, and five weeks postoperatively, the shoulders were harvested and the infraspinatus tendon was subjected to biomechanical testing. Two specimens from each group were used for histological analysis.

RESULTS:

At one week, maximum load, maximum stress, and stiffness were all significantly decreased in Group S compared with the values in Group C. Mean maximum load decreased from 37.9 N in Group C to 27.5 N in Group S ($p < 0.0005$). Mean maximum stress decreased from 18.1 MPa in Group C to 13.6 MPa in Group S ($p < 0.0005$). Mean stiffness decreased from 26.3 N/mm in Group C to 17.8 N/mm in Group S ($p < 0.0005$). At one week, mean maximum stress in Group I+S (17.0 MPa) was significantly decreased compared with the value in Group I (19.5 MPa) ($p < 0.0005$). At both the three-week and the five-week time point, there were no significant differences between Group C and Group S or between Group I and Group I+S with regard to mean maximum load, maximum stress, or stiffness. Histological analysis showed fat cells and collagen attenuation in Groups S and I+S. These changes appeared to be transient.

CONCLUSIONS:

A single dose of corticosteroids significantly weakens both intact and injured rat rotator cuff tendons at one week. This effect is transient as the biomechanical properties of the steroid-exposed groups returned to control levels by three weeks.

PMID:

Summary: Single row repair is more vulnerable to tendon-bone gap formation with early physical therapy which includes arm rotation than is double row rotator cuff repair.

Am J Sports Med. 2008 May;36(5):888-92. Epub 2008 Apr 9.

Biomechanical performance of rotator cuff repairs with humeral rotation: a new rotator cuff repair failure model.

Ahmad CS, Kleweno C, Jacir AM, Bell JE, Gardner TR, Levine WN, Bigliani LU

New York Orthopaedic Hospital, Department of Orthopaedic Surgery, 622 West 168th Street, PH-11th Floor, New York, NY 10032, USA. csa4@columbia.edu

Abstract

BACKGROUND:

Traditional biomechanical evaluations of rotator cuff repair techniques employ cyclic loading of the supraspinatus tendon in an isolated medial direction.

PURPOSE:

This study was conducted to evaluate 2 different rotator cuff repair techniques that are currently the

subject of debate with cyclic loading and with internal and external humeral rotation to better simulate postoperative rehabilitation.

STUDY DESIGN:

Controlled laboratory study.

METHODS:

Nine fresh-frozen paired human cadaver shoulders (18 shoulders) were studied. A single-row repair with 2 suture anchors was compared with a double-row repair with 4 suture anchors. The shoulders were tested in a custom device to position the shoulder in neutral, 45 degrees of internal rotation, and 45 degrees of external rotation. Cyclic loading of the supraspinatus tendon was performed with an MTS material testing machine. Gap formation was measured and analyzed for each rotational position using the MTS device.

RESULTS:

For the single-row repair, average gap formation per 100 cycles in the positions of neutral, internal, and external humeral rotation was 1.47 +/- 0.63, 3.11 +/- 1.55, and 2.24 +/- 0.94 mm, respectively. For the double-row repair, average gap formation per 100 cycles in the positions of neutral, internal, and external humeral rotation was 1.25 +/- 0.54, 2.29 +/- 1.10, and 1.57 +/- 0.48 mm, respectively. For gapping averaged over all positions, the double-row repair had significantly less gapping than the single-row repair ($P = .0109$); gapping was greatest for internal rotation, followed by external rotation, and least for neutral ($P < .0001$).

CONCLUSION:

The testing method of including a rotational component in biomechanical rotator cuff repair testing is a more realistic model of the loading conditions experienced by a repaired rotator cuff as the patient participates in postoperative rehabilitation. Double-row repair has better fixation strength than single-row repairs when exposed to cyclic loading and changes in humeral rotation position.

CLINICAL RELEVANCE:

Humeral rotation affects rotator cuff fixation and should be considered in postoperative rehabilitation.

Summary: Reformation of a normal tendon-bone attachment takes 24 weeks to occur based on histological analysis in an animal model.

J Orthop Res. 2005 Nov;23(6):1433-40.

Formation of a new enthesis after attachment of the supraspinatus tendon: A quantitative histologic study in rabbits.

Koike Y, Trudel G, Uhthoff HK.

The Bone and Joint Research Laboratory, University of Ottawa, 451 Smith Rd, Ottawa, Ont., Canada K1H 8M5.

Abstract

PURPOSE:

To quantify in a longitudinal study non-chondrocytic cells and chondrocytes, tissular architecture as well as extracellular matrix restoration during the formation of an enthesis following supraspinatus tendon **attachment to the humerus.**

METHODS:

In 89 rabbits, one supraspinatus fibrocartilaginous enthesis was resected and the tendon either attached to the greater tuberosity (n=75) or not attached (n=14). The animals were sacrificed after 2, 6, 8, 12 or 24 weeks. The operated and contralateral shoulders were processed for histologic sections. Number of non-chondrocytes, chondrocytes and alignment of chondrocytes in rows were assessed histologically. Extracellular matrix restoration was measured based on (1) area of toluidine blue metachromasia indicating proteoglycan content and (2) on area of diffracted polarized light indicating spatial collagen fiber alignment.

RESULTS:

In the attached tendon, the number of non-chondrocytic cells sharply increased at 2 weeks, progressively decreased thereafter but remained higher than controls at all time points. Chondrocytes appeared at 2 weeks and their number reached control levels by 6 weeks (136+/-14 vs 144+/-15 controls, $p>.05$). The percentage of chondrocytes aligned in rows increased from 19+/-4% at 2 weeks to reach near normal values at 24 weeks (71+/-3% vs 78+/-2% controls, $p>.05$). Area of metachromasia increased from 0.1+/-0.1 mm² at 2 weeks to 3.8+/-0.3 mm² at 24 weeks, still below contralateral enthesis levels (4.6+/-0.1 mm²), $p<.05$). Area of diffracted polarized light enlarged from 12+/-2 x 10³ microm² at 2 weeks to 151+/-19 x 10³ microm² at 24 weeks, still significantly smaller than contralateral levels (177+/-13 x 10³ microm²), $p<.05$). Neither chondrocytes nor metachromasia were observed in the non-attached tendons.

CONCLUSION:

A new enthesis was formed after attachment of the supraspinatus tendon into bony trough. Histomorphometry allowed to document extensive non-chondrocytic proliferation that was followed by appearance of chondrocytes and their spatial organization, a process was complete by 24 weeks. Extracellular matrix formation as well as spatial alignment of collagen fibers were delayed and not complete by 24 weeks. This first longitudinal investigation on the formation of the supraspinatus enthesis using quantitative outcome measures cautions against too early and too aggressive a rehabilitation program.

Summary: The strength of rotator cuff tendon repair is very low in an animal model when measured in the first 6 weeks after surgical repair.

J Orthop Res. 2010 Jun;28(6):710-5.

Supraspinatus tendon repair into a bony trough in the rabbit: mechanical restoration and correlative imaging.

Trudel G, Ramachandran N, Ryan SE, Rakhra K, Uhthoff HK.

Source

Bone and Joint Laboratory, University of Ottawa, Ottawa, Ontario, Canada.
gtrudel@ottawahospital.on.ca

Abstract

Recurrence of tears is a common complication after rotator cuff surgery. Retearing seems to occur early after surgery and may be attributed to too early or too vigorous exercises. We found no experimental data correlating the strength of the rotator cuff early after surgery and imaging. Our objectives were to measure the peak load to failure of rabbit supraspinatus tendon-bone constructs at early times postoperatively, to determine their mode of failure, and to determine whether computed tomography (CT) can predict their strength. We divided one supraspinatus tendon of 40 adult female white New Zealand rabbits and, after resection of the enthesis, sutured the tendon into a bony trough. Ten rabbits were killed immediately and 10 each at 1, 2, and 6 weeks postoperatively. The explanted tendons of both shoulders were imaged on CT and tested to failure. Compared to normal tendons (mean 210 +/- 42 N), the mean strength was very low at 0 weeks (57 +/- 21 N) and 1 week (86 +/- 33 N) (both $p < 0.05$); it had recovered by 6 weeks (324 +/- 66 N). Early on, suture pullout was the most common mode of failure, whereas at 6 weeks, mid-substance tears predominated ($p < 0.05$). Hypoattenuation on CT was associated with increased strength of the tendon-bone construct ($p < 0.05$). The strength of the surgical construct is very low in the early postoperative period. Therefore, the shoulder should be submitted only to loads not interfering with healing

Summary: Muscle atrophy and fat accumulation do not reverse after surgical repair of the rotator cuff.

J Orthop Sci. 2003;8(3):449-56.

Relevance of pathology and basic research to the surgeon treating rotator cuff disease.

Uhthoff HK, Trudel G, Himori K.

Source

Bone and Joint Research Laboratory, University of Ottawa, Ottawa, Ontario, Canada K1H 8M5.

Abstract

For any physician expecting a successful outcome of a treatment regimen a thorough understanding of the underlying pathogenetic mechanism and the pathology of the disease process is an absolute prerequisite. In addition, the surgeon, obviously wishing to obtain a positive outcome of the procedure, must know the reaction of the body to his or her surgical actions. In particular, he or she must be familiar with the factors guaranteeing an uneventful healing process. For example, with rotator cuff disease it is important to realize that the site of degeneration leading eventually to tearing does not lie in the tendon itself but at its insertion into bone. Moreover, the cells and vessels needed for healing after surgical repair do not originate from the torn tendinous stumps. An important source of cells and vessels is the subacromial

bursa overlying the site of tearing. Consequently, the bursa must be preserved at all cost. The subchondral bone trough into which the medial tendon stump is usually anchored during repair represents the other source of healing tissue. Whereas surgeons understandably concentrate their attention on the site of tearing, the fate of the muscle in the torn bone-tendon-muscle unit must not be neglected. In experimental studies we were able to measure muscle atrophy and fat accumulation and could quantify their evolution over time. Finding no reversal of these two parameters after successful repair was disturbing. Shoulder surgeons will benefit from this comprehensive review of updated concepts.

Summary: Nicotine (the active ingredient in cigarette smoke) interferes with tendon healing after rotator cuff repair.

J Bone Joint Surg Am. 2006 Sep;88(9):2027-34.

Nicotine delays tendon-to-bone healing in a rat shoulder model.

Galatz LM, Silva MJ, Rothermich SY, Zaegel MA, Havlioglu N, Thomopoulos S.

Source

Department of Orthopaedic Research, Washington University School of Medicine, 660 South Euclid Avenue, Campus Box 8233, St. Louis, MO 63110, USA. galatzl@wustl.edu

Abstract

BACKGROUND:

Many studies have shown that nicotine negatively impacts fracture healing and bone fusion processes. However, very little is known about its effect on tendon and ligament healing. The goal of the present study was to evaluate the effect of nicotine on tendon-to-bone healing.

METHODS:

Supraspinatus tendons in both shoulders of seventy-two rats were transected and repaired to the humeral head. Osmotic pumps were implanted subcutaneously, and nicotine or saline solution was delivered for ten, twenty-eight, or fifty-six days. Cell morphology was evaluated with use of histologic sections. Cells were counted, and proliferating cell nuclear antigen (PCNA) immunohistochemistry was performed to assess cellular proliferation. In situ hybridization was performed to measure type-I collagen mRNA expression. Biomechanical and geometric properties were assessed.

RESULTS:

Inflammation persisted longer in the nicotine group than in the saline solution group. Cellular proliferation was higher in the saline solution group than in the nicotine group at the early time-points. Type-I collagen expression was higher in the saline solution group at twenty-eight days. Mechanical properties increased over time in both groups. Maximum stress was significantly lower in the nicotine group than in the saline solution group at ten days. Maximum force was significantly lower in the nicotine group than in the saline solution group at twenty-eight days. Maximum force was significantly higher in the nicotine group than in the saline solution group at fifty-six days. Stiffness was not different between the groups at any time-point.

CONCLUSIONS:

Nicotine caused a delay in tendon-to-bone healing in a rat rotator cuff animal model. Mechanical properties increased over time in both groups, but the properties in the nicotine group lagged behind those in the saline solution group. Chronic inflammation and decreased cell proliferation may partly explain the inferior biomechanical properties in the nicotine group as compared with the saline solution group.

CLINICAL RELEVANCE:

Failure of rotator cuff repair is a major clinical problem. The adverse effect of nicotine on rotator cuff healing noted in this clinically appropriate animal model may be an important clinical consideration.